

# Primary Cutaneous Actinomycosis of Lower Extremity: A Rare Case Report

\*Hossain MI,<sup>1</sup> Khan AS<sup>2</sup>

Actinomycosis is a chronic, suppurative, and granulomatous process caused by actinomycetes, saprophytic bacteria normally residing in the oral cavity. There are a few cases of primary actinomycosis described in the literature where it can involve any organ. Primary cutaneous actinomycosis of the lower extremity is very uncommon and can easily be regarded as ordinary soft tissue infection. Herein, a case of 45-year-old diabetic man with primary cutaneous actinomycosis at his lower extremity, over the lateral aspect of left lateral malleolus was reported. He was treated successfully with surgical excision combined with extended period of antimicrobial treatment.

[Dinajpur Med Col J 2015 July; 8 (2):239-242]

**Key words:** Actinomycosis, Extremity, Saliva, Skin

## Introduction

Actinomycosis was first described as a clinical entity over 100 years ago: in fact, the first case of actinomycosis, in man, was described by Von Langebeck, in 1845, and it was attributed to a fungus. Israel and Ponfick, in 1891, defined the anaerobic nature of actinomyces and isolated it in man.<sup>1</sup> *Actinomyces* species are members of the endogenous flora of mucous membranes, and are frequently cultured from the gastrointestinal tract, bronchi, and female genital tract.<sup>2</sup> Actinomycosis is a slowly-progressive infection caused by filamentous, gram-positive, anaerobic (or facultatively anaerobic) bacilli of the *Actinomyces* genus.<sup>3</sup> *A. israeli* is the most frequent pathogen involving human infection.<sup>4</sup> Actinomycosis is a rare, suppurative, granulomatous disease that may involve several organs. It is more

common in males (3:1) and in immunocompromised patients.<sup>5</sup> There are three classic patterns of actinomycosis; i) cervico-facial, involving the jaw extending into the neck, ii) thoracic, and iii) abdomino-pelvic.<sup>6</sup> Cutaneous involvement is well documented and it is usually secondary to local extension or probably to hematogenous spreading from various sites. Primary actinomycosis of extremity is very rare with less than 50 case reports in the literature.<sup>7</sup> Preoperative diagnosis is usually difficult with the majority of cases being diagnosed after the histological and bacteriological examination of the resected specimen.<sup>8</sup> We herein report on a rare case of cutaneous actinomycosis in the lower extremity presenting as a soft tissue mass.

1. \*Dr. Mohammad Ismail Hossain, Lecturer, Department of Pathology, Chittagong Medical College, 4203, Chittagong. ismail.tushar@gmail.com

2. Dr. AKM Shahabuddin Khan, Professor, Department of Pathology, Comilla Medical College, 3500, Comilla.

\*For correspondence

## Case Report

A 45 year old male, smoker, affected by diabetes mellitus, presented with the complaints of swelling over the lateral aspect of the left lateral malleolus for last 1 year. He recalled that the lesion bothered him intermittently and resolved after each treatment with oral antibiotics since the traumatic injury 1 year ago, when he applied his saliva to the lesion for pain relief, what he used to do. His past history was unremarkable.

With these complaints he was admitted to Chittagong General Hospital for operative treatment. There was a soft tissue mass about 4x3 cm in size, with central fluctuation and local heat surrounding by erythematous and swelling changes over the left lateral malleolus. There was no palpable lymphadenopathy in the left leg and inguinal region. Laboratory data revealed a WBC count  $15 \times 10^9/L$  with neutrophilic leucocytosis, haemoglobin of 10 g/dl and C-reactive protein (CRP) 2 mg/dl. The X-ray of lower extremity including ankle joint revealed no significant abnormality. FNAC revealed nonspecific inflammation. It was then clinically diagnosed as soft tissue mass with inflammatory changes and patient underwent local excision of the lesion and the excised specimen was sent for histopathological study.

Macroscopically tissue was irregular and soft in consistency measured 3x3 cm. On cut section a little bit cheesy material came out. Histopathological examination revealed features of actinomycosis. Histologically a necrotizing granulomatous reaction with central aggregates of neutrophils, forming microabscess, was observed. Within the abscess some bacterial colonies consisting of intertwined radiating filaments capped by eosinophilic hyaline material, creating a sunburst pattern/ characteristic structures as

“sulphur granules” and these features are consistent with the diagnosis of actinomycosis (Fig: 1-4). There was no evidence of malignancy. Hence the histomorphological diagnosis of actinomycosis was made and the patient was treated with amoxicillin/clavunilate antibiotics. He was discharged on the 10<sup>th</sup> hospital day to continue maintenance therapy with doxycycline for 8 weeks. The patient is now under maintenance therapy and there is no recurrence till now.

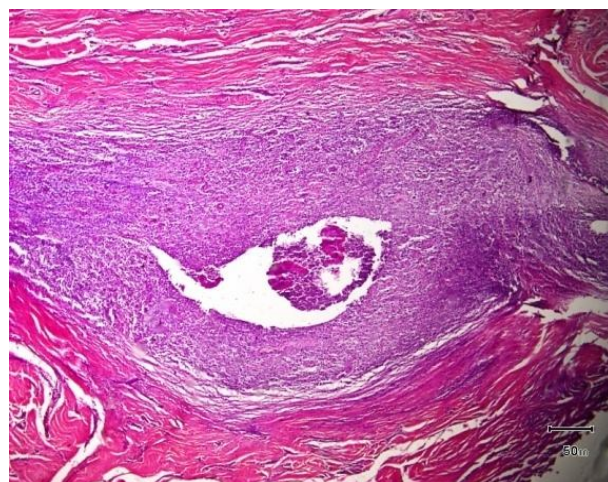


Fig: 1. Actinomycotic abscess (40X, H & E stain)

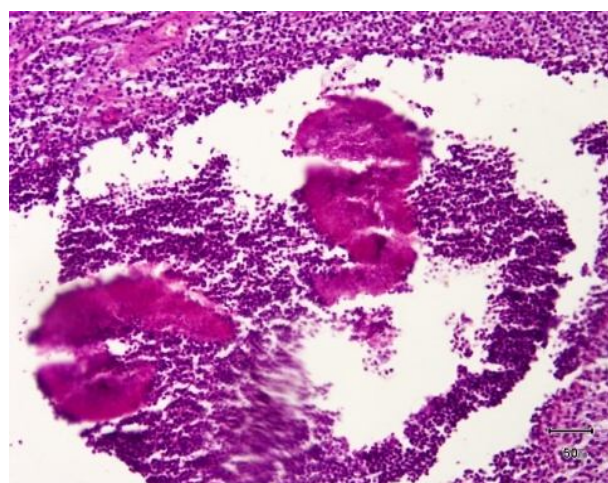


Fig: 2. Two actinomycotic colony (100X, H & E stain)

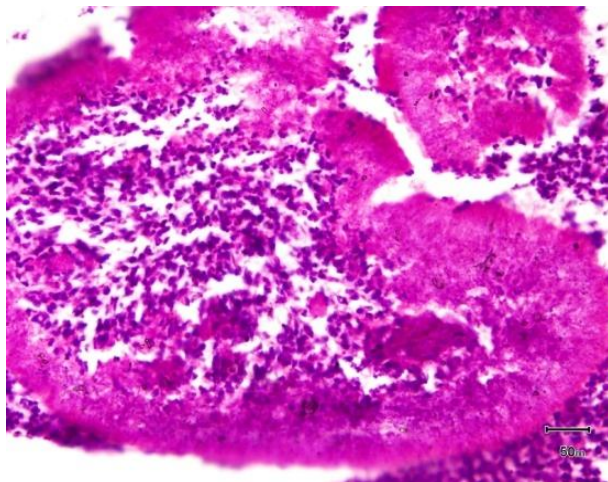


Fig: 3. Actinomycotic colony (200X, H & E stain)

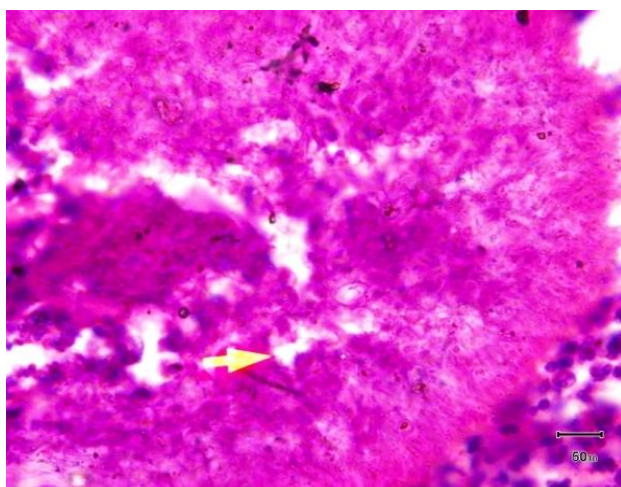


Fig:4: Filamentous colony of actinomycosis (400X, H & E stain)

### Discussion

Actinomycosis is a chronic disease involving mainly cervicofascial, thoracic and abdominal regions. The infection is characterised by abscess formation, draining sinuses and tissue fibrosis. Main pathogens are *Actinomyces israelii* or *A.naeslundii*. *Actinomycetes* sp. is strictly a commensal of the oropharynx, gastrointestinal and female genital tracts therefore Actinomycosis is usually secondary to trauma to these area. Intrauterine device may predispose a patient to Actinomycosis of the genital tract.<sup>9</sup> In addition, animals may also carry this microorganism in different

species but cause similar disease. It has never been found in soil, in plants, or in any other object outside the body. Most of the infection occurred after traumatic injury that creates an anaerobic conditions predisposing to this microorganism, and most commonly associated with other bacterial infections. Because of the exclusively endogenous habitat of the etiologic agent, head and neck, thorax, and abdomen are the sites that commonly involved. This microorganism is less virulent than ordinary bacteria. Sulfur granules (grains) containing filamentous or club-shaped structures that are Gram-positive but negative with acid-fast staining are usually found in pus or tissue specimens. Primary actinomycosis of the extremity is very uncommon. This infection usually occurs after direct inoculation after traumatic injury or bites, or less commonly disseminated from primary focus.<sup>7</sup> The predisposing factors are represented by debilitating conditions such as malignancy, diabetes, and immunosuppression such as leukemia, lymphoma, renal insufficiency, and renal transplant.<sup>8</sup> Its clinical presentation is usually indolent and has various manifestations, including nodular lesions, subcutaneous abscess, or even mass lesion mimicking tumor. Appropriate sampling and histopathological examination are necessary to confirm actinomycosis.<sup>7</sup> Imaging techniques such as CT and MRI usually yield nonspecific findings, contributing only to define radiological features of the mass and its involvement in adjacent soft tissues. Diagnosis may be difficult because of a general lack of familiarity with the disease and a low success rate in culturing the organism as a result of its fastidious nature. Isolation of the organism and its identification take from 2 to 3 weeks (it grows slowly). Cultures should be placed immediately in anaerobic conditions and incubated for approximately 48 hours. FNAC is the method of choice in the diagnosis of cervical

actinomycosis. It is an easy, safe, rapid and highly effective method.<sup>1</sup> Actinomycosis needs to be considered when the patient has chronic progression of the disease across tissue planes, mass-like at times, which may heal and recur, after a typical course of antibiotics.<sup>8</sup> Although culture is definitive, however, it is difficult to cultivate *Actinomyces* spp. from clinical specimens. Therefore, the single most helpful diagnostic maneuver for actinomycosis is to demonstrate sulfur granules in pus or tissue specimens.<sup>7</sup> In this reported case, the diagnosis of actinomycosis is based on the histopathological finding with the typical feature of sulfur granules in pus. Hematogenous seeding is the most likely pathogenesis in patients with primary cutaneous actinomycosis according to the literature review. However, in this case, direct inoculation of *Actinomyces* spp. from his saliva to his traumatic wound is the presumed pathogenesis.

In conclusion, we report a unique case of actinomycosis resembling a soft tissue mass in its clinical features and X-ray findings. This case report emphasizes the importance that *Actinomyces* sp. is a normal inhabitant of the oral cavity, clinical illness may develop after direct inoculation of this microorganism from saliva into a preceding wound in extremities. Because of its rarity, the documentation of more cases is required to define the pathogenesis in much detail.

## References

1. Lancella A, Abbate G, Foscolo AM, Dosdegani R. Two unusual presentations of cervicofacial actinomycosis and review of the literature. *Acta Otorhinolaryngol Ital* 2008; 28: 89-93.
2. Na KY, Jang Ji-H, Sung Ji-Y, Kim YW, Park Y-K. Actinomycotic brain abscess developed after 10 years of head trauma.

- The Korean Journal of Pathology 2013; 47: 82-85.
3. Smith MH, Harms PW, Newton DW, Lebar B, Edwards SP, Aronoff D. Mandibular actinomyces osteomyelitis complicating florid cement-osseous dysplasia: a case report. *BMC Oral Health* 2011; 11:21: 1-6. <http://www.biomedcentral.com/1472-6831/11/21>.
4. dos Santos JWA, Zambenedetti RM, Mann KC, Cibin LFX. Thoracic actinomycosis-Report of a patient with advanced-stage disease. *The Brazilian Journal of Infectious Diseases* 2007; 11(1): 157-159.
5. Ramos MIA, Carneiro JA, de Oliveira Poswar F, Nassau DC, Colares FA. Actinomycosis affecting spinal cord: a case report. *SOCIE DADE BRASILEIRA MEDICINA TROPICAL*; 2007: 1-3.
6. Akhtar K, Naim M, Ahmad SS, Khan N, Abedi U, Khan AK. Actinomycosis- Left post chest wall. *JK SCIENCE* January-March 2008; 10(1): 37-38.
7. Yang C-H. Primary cutaneous actinomycosis of an extremity: a case report. *J Intern Med Taiwan* 2010; 21: 290-293.
8. Vishwanathan B, Ganesh MH, Kavitha R, Pinnelli VBK. Actinomycosis masquerading as soft tissue tumor of the thigh: a rare case report. *Int. J Clin. Diag. Res.* 2013; 1(1): 1-6.
9. Yusof MI, Yusof AH, Salleh MSM, Harun A. Actinomycosis of knee. *Malayasian Journal of Medical Sciences*, January 2005; 11(1): 68-69.