

## Placenta in Situ – 9 Years Follow up in a Case of Advanced Viable Extrauterine Pregnancy Extraction

\*Alam MF

Advanced extrauterine pregnancy with a successful outcome is a rare event. Though relatively rare, advanced abdominal pregnancy (AAP) can have dramatic and catastrophic consequences for the fetus and the mother. Difficult to diagnose pre-operatively, AAP presents special challenges to the physician working in remote areas with limited resources for diagnosis and management. A case is presented of a 30-years-old woman at 35 weeks gestation whose abdominal pregnancy was successfully managed. The diagnostic and management problems associated with abdominal pregnancy are discussed, and especially the controversial issues of the treatment of the placenta after delivery. This case is specially reported because of the information of the placenta left in situ after extraction of the baby and membranes even after 9 years. The reasons for the high maternal and perinatal mortality associated with the condition are also analyzed.

[Dinajpur Med Col J 2015 July; 8 (2):232-238]

**Key words:** Extrauterine pregnancy

### Introduction

**E**xtrauterine abdominal pregnancy is a very rare form of ectopic pregnancy where implantation occurs within the peritoneal cavity, outside the fallopian tube and ovary. It is estimated to occur in 10 out of 100,000 pregnancies in the United States,<sup>1</sup> whereas advanced abdominal pregnancy is encountered 1 in 25000 births.<sup>2</sup> The diagnosis of such a condition is frequently missed during antenatal care, despite the routine use of abdominal ultrasonography. However, it is extremely important to detect an extrauterine abdominal pregnancy because the associated maternal mortality rate is estimated at about five per 1000 cases, which is approximately seven times higher than the estimated rate for ectopic pregnancy in general, and about 90 times the maternal mortality rate associated with normal delivery in the United States.<sup>1,4</sup>

Survival of the newborn is also affected with a perinatal mortality rate of 40% to 95%.<sup>3,4</sup> We report on a successful operative delivery

of a healthy baby following a 35 wks extrauterine abdominal pregnancy in a multigravida in whom the diagnosis was missed despite repeated ultrasonography during the antenatal period.

### Case Report

The patient was a 30-years-old woman from Nilphamari, Northern District of Bangladesh. Previously she had one normal vaginal delivery in her village in 1992. There were no postpartum complications and no history of any previous gynaecological problems, especially pelvic inflammatory disease except secondary infertility of unknown aetiology. Her menses were normal and regular, and there was no relevant past medical, surgical or family history. She was on regular ante natal check up under Mother and Child welfare centre (MCWC) at Nilphamari under Directorate of Family planning, Government of The People's Republic of Bangladesh.

\*Professor Dr. Mohammed Faisal Alam, Department of Gynae and Obs, Dinajpur Medical College, Dinajpur

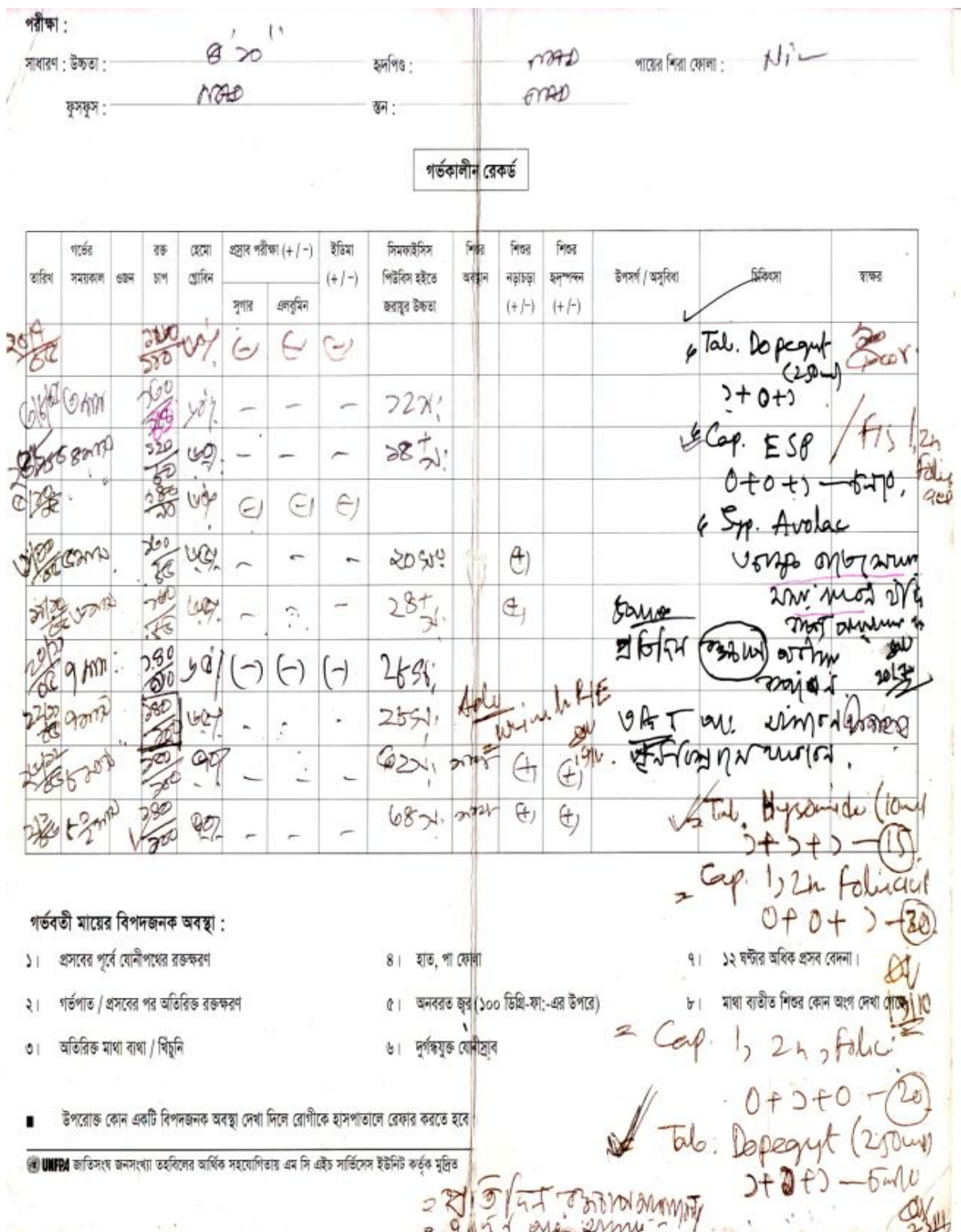


Figure 1. ANC card of MCWC

According to the recordings in the card, on her 1<sup>st</sup> antenatal check up at 11 weeks of pregnancy she was hypertensive, her blood pressure was 160/100 and she was advised tab methyldopa 250 mg 8 hourly at that time. With methyldopa her blood pressure was well controlled, but it again started to rise at 28 wks and till term her BP was 150/100. Her hemoglobin was 60%. Other parameters were normal. An ultrasonogram was done on 13/11/2005 which reported “About 28 weeks of single viable pregnancy with cephalic presentation, liquor adequate and placenta fundal, anterior”.

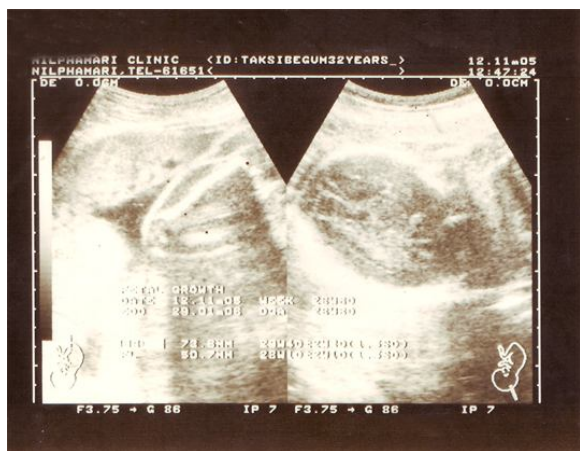


Figure 2. Ultrasonographic picture of about 28+ wks of viable pregnancy with cephalic presentation without any comment about AAP (misinterpretation).

Except elevated blood pressure her pregnancy was uneventful. But the Hb tend to fall to about 50% after 32 weeks pregnancy and as blood pressure was not controlled by methayldopa, Nifedipin was added at 32 weeks. At 33 weeks she came to MCWC with the complaints of less fetal movement and even with Nifedipine, blood pressure was uncontrolled. Then the doctor increased the dose of methyldopa 2 tab tds and referred the patient to higher centre. Then the patient came to me at Dinajpur on 5/1/2006 with the complaints of less fetal movement, whole

abdominal pain. On examination I found so called symphysio-fundal height 34 cm, vague abdominal pain, easily palpable fetus with oblique lie, heart sound within normal limit. Then I advised an Ultrasonography which commented that “about 34 weeks viable pregnancy with cephalic presentation scanty liquor and placenta anterior, fundal”

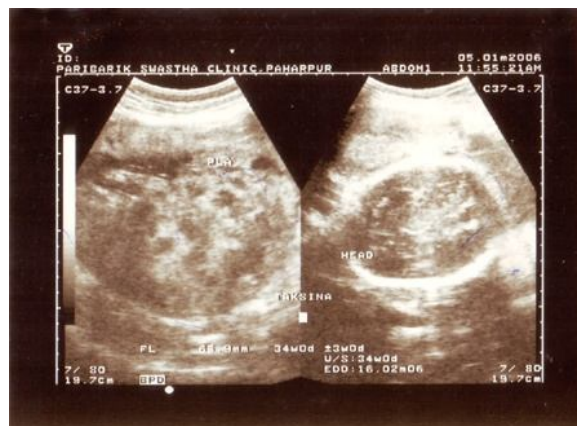

Figure 3. Another ultrasonographic picture of commenting 34 wks single viable pregnancy with scanty liquor without any comment about AAP (misinterpretation)

On vaginal examination the cervix was tubular and soft. Arrangements were made for caesarean section under sub arachnoid block. Abdomen was opened with Pfannenstiel incision. On opening the abdomen it was full of blood. Uterus was found in midline. Behind that the pregnancy sac was found which looked like a big mucinous ovarian cyst and the wall of the sac was so thick and pearly white that the baby wasn't seen through it. But on palpation fetal parts were felt.

The amniotic membrane was dissected and incised and the live male fetus was extracted weighing 2500 grams. The fetal Apgar scores were 6 and 10 at one and five minutes, respectively. There was no congenital anomaly of the baby except the mechanical facial deformity due to compression by the ribs. Baby was removed with part of the cord.



The placenta was found attached to left lobe of the liver, pancreas, spleen and the membranes were attached to lateral abdominal wall and posteriorly in the nest of intestine. Then I have taken the help of an expert surgeon and asked for more bags of blood. Then the membranes were stripped of from the line of attachment resulting in multiple small oozing points. Cord was cut short as close as to the placenta and as because the placental blood supply was so extensive involving major abdominal vessels it was considered too risky to attempt removal. The placenta left in situ accordingly, 15 figure of 8 haemostatic sutures were placed at the circumference of the placenta. The abdomen was as a whole checked by me and the surgeon after giving inverted T incision over the Pfannenstiel incision. An abdominal Drain was inserted to drain the placental bed. Blood loss of approximately 1300 ml during the operation was replaced with seven units of whole blood and packed cells also.

The patient made an excellent convalescence; there were no postoperative problems in resuscitation or in analgesia or respiratory. A postoperative haemoglobin of 7.8 g/dl was corrected with a further two units of packed cells. Her operative period and 1<sup>st</sup> post operative day were covered with Ceftriaxone and from 2<sup>nd</sup> post operative day cefuroxime.

Patient was discharged on 11<sup>th</sup> POD. After 7 days of discharge the patient presented with left hypochondriac pain. Ultrasound examination showed that the placental mass presented in the left hypochondriac region had decreased significantly in size. Then patient was advised for Methotrexate 50 mg daily for 6 days and inj Leucovorin 6mg for 1 day (Rescue therapy ) and the nature of mass was explained to the patient and her husband. But patient lost from my follow -up and had gone to their relative doctor

(ultrasonographer) and that ultrasonographer also consulted to me and I explained the matter also to him. Possibly they didn't take the rescue therapy. Then the pt. again came after 6 weeks with the complaints that there was no pain in the left hypochondriac region, but pain in the left iliac fossa. USG showed that the placental mass has dropped in the left iliac fossa from the left hypochondriac region. After 9 years the pt has no complaints just with my interest I have done one ultrasonogram and found the placental mass in the size 6.5 x 6.3 cm in the left ovarian region.

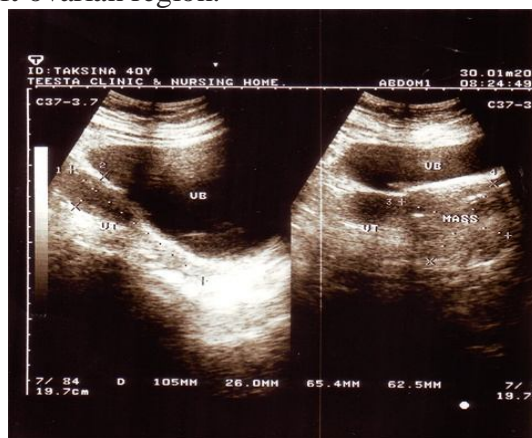


Figure 4. Echogenic mass in left side of pelvic cavity and her serum  $\beta$ -HCG level is within normal limit.



Figure 5. Picture showing that boy with his parents at the age of 9 in 2015

## Discussion

The management of abdominal pregnancy is a formidable challenge to the most skilled obstetricians. It is a potentially life-threatening condition, especially in developing countries; where diagnosis may be delayed. Its incidence is a reflection of the degree of pelvic inflammatory disease and ectopic pregnancy in particular communities. The highest incidence in the world is in the South African Bantu, where it is stated that 2.2% of ectopic pregnancies are of the abdominal variety.<sup>1</sup> Port Moresby General Hospital statistics reveal an incidence of 1 abdominal pregnancy per 62 cases of ectopic pregnancy, giving a rate of 1.6%.<sup>3</sup> Extrauterine abdominal pregnancy beyond 20 weeks gestation and with a viable fetus is a rare condition, with an estimated prevalence of one out of 8099 hospital deliveries.<sup>3</sup> About 21% of babies born after an extrauterine abdominal pregnancy have birth defects, presumably due to compression of the fetus in the absence of the amniotic fluid buffer. Typical deformities include limb defects, facial and cranial asymmetry, joint abnormalities and central nervous malformation.<sup>5</sup> In this case, the baby was protected by the surrounding amniotic fluid and sac which could explain the absence of deformities in the baby. Perinatal mortality associated with abdominal pregnancy is also very high, this is largely related to the friability and vascularity of the placental implantation site with fetal growth retardation and fetal abnormalities both being major problems.

Abdominal pregnancies may be classified as primary or secondary. In a primary abdominal pregnancy there is direct implantation on the peritoneal surface and this is associated with anatomically normal fallopian tubes, ovaries and uterus. A secondary abdominal pregnancy results from displacement of the fertilized ovum from the fallopian tube or from the

uterus to its new site. The case described in this case report is almost certainly a primary abdominal pregnancy. However, such a classification has little practical clinical relevance for diagnosis and appropriate therapeutic management.

The key to the successful management of advanced abdominal pregnancy (AAP) is early diagnosis to avert massive haemorrhage secondary to placental disruption and separation. Suggestive clinical findings are recurrent lower abdominal pain, an unstable lie and the detection of a separate mass from the amniotic sac containing the fetus. Evidence of poor fetal growth may also be present. On vaginal examination the finding of a radically displaced anterior and uneffaced cervix has been reported.

A plain lateral X-ray of the abdomen and the fetus confirms the diagnosis of advanced abdominal pregnancy by showing the presence of fetal parts superimposed on the maternal spine. This is particularly important for clinicians in developing countries where there are no ultrasound or magnetic resonance imaging facilities.

An experienced ultrasonographer will confirm the presence of an extra uterine pregnancy by showing the amniotic sac to be separate from the uterus. Fetal growth retardation and fetal abnormalities may also be present.

Magnetic resonance imaging (MRI) is an excellent modality to assess the definitive area of placental implantation. However, it is not available in many centers and is rarely required. Combined with ultrasound it may be useful in follow-up of placental involution postoperatively.

Experience has shown that in 50% or more of cases the diagnosis of abdominal pregnancy is not anticipated because the condition has been overlooked. The management of abdominal

pregnancy clearly depends on the stage at which it is diagnosed. If diagnosed before 28 weeks gestation then conservative management is feasible provided the following criteria are followed:

1. Absence of a major congenital malformation.
2. A live fetus.
3. Continuous hospitalization in a well equipped and well-staffed maternity unit with immediate blood transfusion facilities available.
4. Careful monitoring of maternal and fetal wellbeing.
5. Placental implantation in the lower abdomen away from the liver and spleen.

Once sufficient viability is reached (after 28 weeks gestation) immediate laparotomy and delivery is recommended. However, there is little published information on the duration of conservative treatment that can be safely employed beyond this stage to gain further fetal maturity. If an abdominal pregnancy with a live and structurally normal fetus is diagnosed after 28 weeks gestation immediate laparotomy and surgical removal of the pregnancy is recommended. It is important to have at least six units of blood cross matched and to have in attendance an experienced obstetric surgeon, paediatrician and, if possible, an experienced vascular surgeon.

In a situation when there is fetal death in utero in an advanced abdominal pregnancy the fetus should be delivered as soon as possible because the patient is at greater risk of disseminated intravascular coagulation. It is important to take all the necessary steps to minimize operative risks and for the placenta to be managed in the same manner as with a viable fetus.

There is continuing controversy with regard to the management of the placenta. Whether the abdominal pregnancy is early or advanced, it is recommended that the

umbilical cord to be ligated as close as possible to the placenta. The removal of the placenta is likely to be associated with torrential and uncontrollable intra abdominal haemorrhage. A useful procedure, as was used in this case, is to insert figure of 8 sutures at the periphery of the placenta to control any bleeding that may subsequently occur. A drain site is always put down to the placental bed. It is accepted that leaving the placenta in situ does increase the risk of subsequent paralytic ileus and intra abdominal sepsis. However, these risks are much less than the likelihood of severe haemorrhage associated with attempted placental removal. Ombelet et al.,<sup>1</sup> in a large series of advanced abdominal pregnancies, reported recently that the placenta was completely removed in 58% of cases and left in situ in the remaining 42%. Where the placenta is left in situ, it may continue functioning for a number of weeks, and even as long as five and a half years. Both serial beta-HCG levels and MRI can be used to follow up placental involution.

Methotrexate may be used to hasten placental involution, as we advised in this case. However, the side-effects of methotrexate have to be balanced against the usefulness of achieving an increased rate of dissolution of placental tissue.

After an abdominal pregnancy the prognosis for the future depends essentially on whether the fallopian tubes and ovaries are normal and conserved at the time of the laparotomy. In the case described of a primary abdominal pregnancy it would appear that this patient's future fertility would be unaffected.

#### *Conclusion*

This is a report of an extrauterine abdominal pregnancy which is a primary AAP. The pregnancy continued uneventfully to 35 weeks and ended successfully with operative

delivery of a healthy baby. The importance of this case report is the fact that an extrauterine abdominal pregnancy could be missed during antenatal care despite repeated ultrasound examinations. Furthermore, the antenatal diagnosis of advanced extrauterine pregnancy does not necessarily justify the termination of the pregnancy since good maternal and fetal outcome is not uncommon.

### References

1. Ombelet W, Vandermerwe JV, Van Assche FA. Advanced extrauterine pregnancy: description of 38 cases with literature survey. *Obstet GynecolSurv* 1988;43:386-397.
2. Desai BR, Patted Shobhana S, Pujar Yeshita V, Ruge J. Advanced Secondary Abdominal Pregnancy following Rupture of Rudimentary Horn, *J Obstet Gynaecol India* 2005;55(2):180.
3. Obstetrics and Gynaecology Department. Port Moresby General Hospital Obstetrics and Gynaecology Department Annual Report 1992. Port Moresby: Port Moresby General Hospital, 1993.
4. Martin JN Jr, Sessums JK, Martin RW, Pryor JA, Morrison JC. Abdominal Pregnancy: Current Concepts of Management. *Obstet Gynaecol.* 1988;71:549-557[PubMed].
5. Stevens CA: Malformations and deformations in abdominal pregnancy. *Am J Med Genet* 1993, 47:1189-1195.
6. Ubels R. Advanced abdominal pregnancy: diagnosis and management. *Trop Doct* 1989;19:77-80.