

## Primary Duodenal Tuberculosis Causing Gastric Outlet Obstruction-A Case Report

\*Basunia M A,<sup>1</sup> Khan S I,<sup>2</sup> Shakir MW,<sup>3</sup> Ahmed A,<sup>4</sup> Jahan MI<sup>5</sup>

Among the gastrointestinal tuberculosis involvement of ilio-caecal region is common but duodenal tuberculosis is very rare. Preoperative diagnosis of duodenal tuberculosis is difficult for surgeons. Here in, we report a case of primary duodenal tuberculosis in a 19 year old female patient admitted in the Rangpur Medical College Hospital with symptoms of gastric outlet obstruction. Endoscopy of upper GIT revealed stricture at the junction of 1<sup>st</sup> and 2<sup>nd</sup> part of duodenum. Endoscopic biopsy was taken and histopathological examination showed features of tuberculosis. The patient was underwent an exploratory laparotomy and gastrojejunostomy. There was a circumferential thickening at the junction of 1<sup>st</sup> & 2<sup>nd</sup> part and also 3<sup>rd</sup> part of duodenum and an excisional biopsy was taken from an enlarged paraduodenal lymph node. Histopathological examination was consistent with gastrointestinal tuberculosis. The patient was started on 6 months regimen anti tubercular chemotherapy and had improved on discharge. The patient was reviewed after 5 months and found symptom free.

[Dinajpur Med Col J 2013 Jul; 6 (2):196-200]

**Key words:** Duodenum, tuberculosis, stricture

### Introduction

**T**uberculosis is very common in developing countries like Bangladesh. Pulmonary tuberculosis is the most frequent manifestation. Patients with gastrointestinal tuberculosis also seen among

which ilio-caecal involvement is found commonly .Duodenal tuberculosis is rarer and usually results from secondary spread from pulmonary tuberculosis. Primary duodenal tuberculosis is so rarer that very few cases are reported till now.<sup>1</sup>

1. \*Dr. Md. Moksed Ali Basunia, Associate professor, Department of Surgery, Rangpur Medical College Hospital.
2. Dr. Md. Saiful Islam Khan, Indoor medical officer, Department of Surgery, Rangpur Medical College Hospital.
3. Dr. Md. Washif Shakir Indoor medical officer, Department of Surgery, Rangpur Medical College Hospital.
4. Dr. Afroza Ahmed, Lecturer, Department of Physiology, Rangpur Medical College.
5. Dr. Mst. Israt Jahan, Indoor Medical Officer ,Department of Gynae&Obstetrics, Rangpur Medical College Hospital.

\*For correspondence

### Case Report

A young, Unmarried, 19 years aged female student, Afsana Parvin hailing from Sayedpur, Nilphamari, Bangladesh, admitted in Gastroenterology department of Rangpur Medical College Hospital on 7<sup>th</sup> May, 2012, with the complaints of loss of appetite for 5 months, vomiting for 3 months, significant weight loss for 3 months. There was history of sensation of fullness after meals. Initially vomiting occurred once daily and usually at the evening, but later on the frequency of vomiting increased and occurred after each meal. Vomiting was spontaneous and contained undigested food particles. Vomiting was not bile stained. There was no history of fever, upper abdominal pain, haematemesis and melaena, jaundice or any urinary complaints. There was no history of chronic cough or haemoptysis. The patient had no known co-morbidities and no history of hospitalization, no history of exposure to tuberculosis. Family history was unremarkable. Physical examination revealed the patient was malnourished, mildly anaemic, mildly dehydrated, fullness in epigastrium even several hours after meal. Stomach was distended and dilated on percussion. Succussion splash was present. The patient was not icteric.



Figure 1. Barium meal X-ray of stomach and duodenum

There was no palpable accessible lymph node. Examination of other systems revealed no abnormality. Complete blood count was normal except Hb% 9.5 gm/dl, lymphocyte count was 50%, ESR was 110 mm at the end of 1<sup>st</sup> hour. Chest X-ray was normal, ultrasonogram of whole abdomen was normal. Barium meal x-ray of stomach and duodenum showed narrowing of 2<sup>nd</sup> and 3<sup>rd</sup> part of duodenum [Figure 1].

Endoscopy of upper gastrointestinal tract reveals stricture at the junction of 1<sup>st</sup> & 2<sup>nd</sup> part of duodenum and endoscope could not be passed beyond this. Biopsy was taken from the strictured area which showed chronic inflammatory cells, epithelioid granuloma, multinucleated giant cells suggestive of tuberculosis [Figure-2].

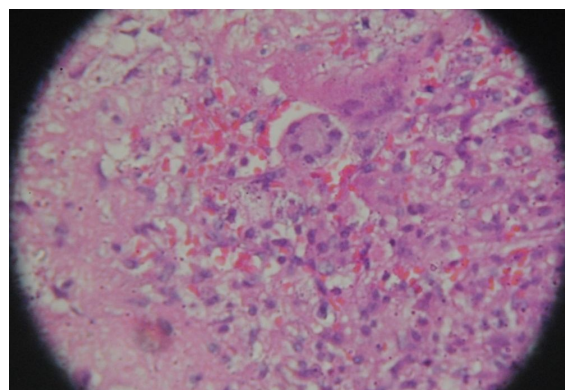


Figure 2. Histopathological slide of duodenum showing multinucleated giant cell

There was no evidence of malignancy. The patient was referred to the department of surgery. An exploratory laparotomy was performed through upper midline incision. Stomach and 1<sup>st</sup> part of duodenum were found dilated. Circumferential thickening was found at the junction of 1<sup>st</sup> part & 2<sup>nd</sup> part [Figure-3] and also part of 3<sup>rd</sup> part of duodenum. There was an enlarged paraduodenal lymphnode along the medial border of 2<sup>nd</sup> part of duodenum. During

excision biopsy of lymphnode caseating materials came out [Figure-4] .There was no evidence of other lymphadenopathy.

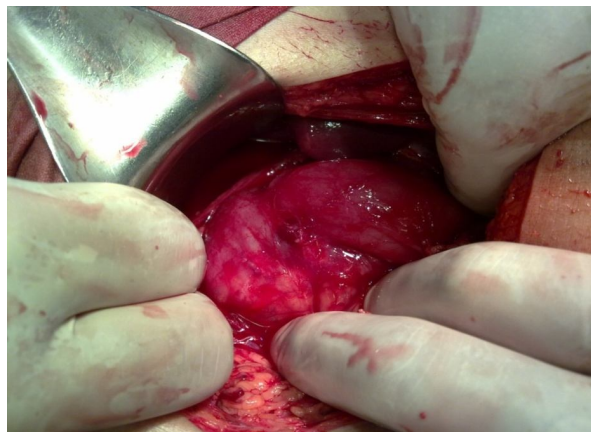


Figure 3. Circumferential thickening at the junction of 1<sup>st</sup> part & 2<sup>nd</sup> part and also part of 3<sup>rd</sup> part of duodenum.

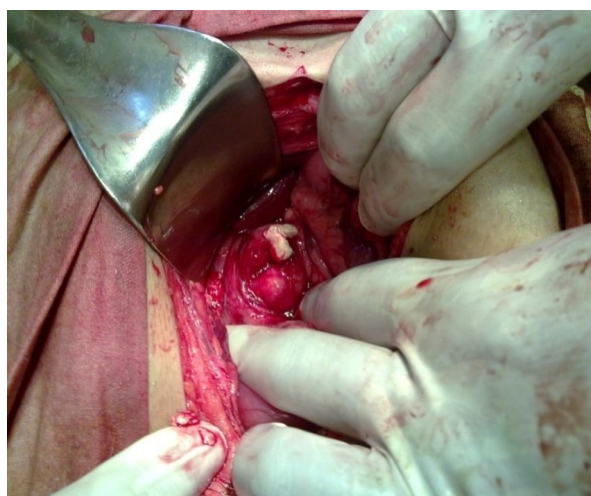


Figure 4. Enlarged paraduodenal lymphnode along the medial border of 2<sup>nd</sup> part of duodenum

Other intra abdominal organs were checked and found normal. Retrocolic isoperistaltic gastrojejunostomy was done. Abdomen was closed in layers keeping drain tube in Morison's Pouch. Postoperative recovery was uneventful.

Biopsy was sent for histopathological examination. Histopathology of lymphnode biopsy showed caseating necrosis, epithelioid granuloma compatible with tuberculosis. The patient was then diagnosed as having duodenal stricture due to primary duodenal tuberculosis. The patient was started on 6 months regimen anti-tubercular medication and had improved on discharged. At follow-ups up to 5 months she was found satisfactorily healthy and normal.

### Discussion

Patients presented with features of gastric outlet obstruction are commonly diagnosed as pyloric stenosis due to chronic peptic ulcer disease or carcinoma antrum of stomach. If either peptic ulcer disease or malignancies cannot be confirmed clinically and by investigations, then possibilities of other causes should be kept in mind and need to be investigated in that line.<sup>1</sup>

In areas where tuberculosis is more prevalent, gastric outlet obstruction may occur as a result of gastroduodenal tubeculosis. Though gastrointestinal tuberculosis usually involves iliocaecal region, stomach and duodenum are seldom affected. The bactericidal property of gastric acid along with motor activity of the stomach and scarcity of lymphoid tissue in gastric wall are reasons for infrequent involvement of gastroduodenal area.<sup>2</sup> Gastrodudenal tuberculosis may be primary or may be secondary from pulmonary tuberculosis. Secondary duodenal tuberculosis results from swallowing of sputum .

The possible routes of primary duodenal tuberculosis are – 1) haematogenous spread, 2) lymphatic spread, 3) spread from serosa by continuity from adjacent structures like lymphnodes.<sup>2</sup>

Duodenal tuberculosis may be classified into two categories, namely Ulcerative and Hyperplastic.<sup>3</sup>

In case of hyperplastic type, gradual narrowing of lumen occurs which causes incomplete luminal obstruction or ultimately complete obstruction.

Clinical diagnosis of duodenal tuberculosis is difficult as there is no pathognomic clinical features. Clinical manifestations are as follows:

1. **Gastric outlet obstruction-** This is the most common presentation in the form of upper abdominal pain, sense of epigastric fullness after meals, vomiting.
2. **Dyspeptic symptoms** of abdominal discomfort, bloating, nausea.
3. **Constitutional symptoms of tuberculosis-** fever, night sweating, fatigue, anorexia and weight loss.
4. **Other symptoms-** upper gastrointestinal tract bleeding, fistula formation with adjacent organs like bilio-duodenal fistula,<sup>1</sup> aorto-duodenal fistula<sup>4</sup> and mesenteric artery duodenal fistula.<sup>5</sup>

Gupto et al reported 30 cases of duodenal tuberculosis patients, including 22 patients showed duodenal obstruction; Cao Tao et al reported 16 cases, showed gastroduodenal obstruction in 13 cases. So, a high index of suspicion is needed if a patient with gastric outlet obstruction comes from tuberculous endemic areas.

Barium meal x-ray of stomach and duodenum shows one or combination of mucosal ulceration, polypoid growth, luminal narrowing, extrinsic compression and proximal dilatation.<sup>6</sup> Endoscopy is not conclusive. Endoscopic biopsy may show non specific inflammation. Most case reports diagnosed duodenal tuberculosis postoperatively. Diagnosis is confirmed

through histopathological findings of caseation necrosis and Langhans type of giant cell.

Treatment of duodenal tuberculosis may be as follows-

- a) **General treatment of the patient-** Improvement of general condition of the patient and relieve of symptoms.
- b) **Medical treatment-** Conventional anti-tubercular chemotherapy for 6 months if there is no complication.
- c) **Surgical treatment-** this is indicated if there is any complications like complete luminal obstruction. Surgery confirm the diagnosis as well as treat the complications. In case of complete duodenal obstruction bypass operation is done mostly in the form of gastrojejunostomy.
- d) **Postoperative anti-tubercular treatment-** Irrespective of surgical methods postoperative antitubercular chemotherapy is given in conventional ways.

#### *Conclusion*

Prognosis depends on early diagnosis and timely treatment. Before appearance of anti tubercular drugs there was poor prognosis and high mortality in intestinal tuberculosis. Patients without complications can be completely cured with anti tubercular drugs. But combination of chemotherapy and modern surgical interventions is required for better prognosis of intestinal tuberculosis with complications like gastric outlet obstruction or others. Though duodenal tuberculosis is rarer, it should be kept in mind if patient with gastric outlet obstruction comes from tubercular endemic areas.

**References**

1. Haydee Buluran Flores, Felix Zano, Ena Lyn Ang, and Norberto Estanislao World J Gastrointest Endosc. 2011 January 16; 3(1): 16–19. Published online 2011 January 16. doi: 10.4253/wjge.v3.i1.16
2. Chawla I, Aery V, Singh K, Singla B, Singh V. Duodenal tuberculosis presenting as gastric outlet obstruction. JSCR 2012 7:13
3. Neil J.McC.Mortensen and Shazad Ashraf. The small and large intestine, Bailey & Love's, SHORT PRACTICE of SURGERY, 25<sup>th</sup> edition, 2004;1174-1175,338 Euston Road, London.
4. Chaudhary A, Bahn A, Malik N, Dilawari JB and Khanna SK. Choledocho-duodenal fistula due to tuberculosis. Indian J. Gastroenterol. 1989. 8:293-294
5. Kodaira Y, Shibuya T, Matsumoto K, Uchiyama K, TenjinT, Yamada N and Tanaka S. Primary aortoduodenal fistula caused by duodenal tuberculosis without an abdominal aortic aneurysm. A report of a case. Surg.Today. 1997. 27:547-548
6. Rao YG, Pande GK, Sahni P, Chattopadhyay TK. Gastroduodenal tuberculosis management guidelines, based on a large experience and a review of the literature. Can J Surg. 2004. 47:364-368
7. Chavhan GE, Ramakantan R. Duodenal tuberculosis: radiological features on barium studies and their clinical correlation in 28 cases. J Postgrad Med. 2003;49:214–217. [[PubMed](#)]